

## Asses microvascular densities in breast ductal cell carcinoma (using CD 31 & VWF immunostain), in correlation to ER status

Ali Zeki Najji and Hedel A. Kerbel

### الخلاصة

خلال الفترة من كانون الثاني 2009 إلى كانون الأول 2011م جمعت 50 حالة سرطان الثدي موجبة لمسقبل الاسد (تحوالجين) و50 سرطان الثدي سلبية لمسقبل الاستروجين من بين حالات سرطان الثدي عند النساء والتي كانت ترسل إلى مختبرم. الحلة التعليق في طلع لمي كثافة الأوعية الدموية له فوالأباصت عمل معلمات الأوعية الدموية المناعية (VWF & CD 31) ووجدت الدراسة إن الوسيط حسب ابي للأوعية الدموية حسب صبغة CD 31 و18 حالات الأورام الموجبة لمستقبل الاستروجين ولحالات الأورام السالبة لذلك المستقبل في حين أن الوسيط الحسابي حسب صبغة VWF هولوا حالات الأورام الموجبة لمسقبل الاسد تروجين و33 لحالات الأورام السالبة لذلك المستقبل بعد هذه الفروقات في كثافة الأوعية الدموية لدي الموجبة والسلبية لمسقبل الاسد تروجين فروقات م وثرة من الناحية الإحصائية ( $p < 0.001$ ). كما وجدت الدراسة إن صبغة VWF تعتبر أفضل من صبغة CD-31 في الكشف عن الأوعية الدموية في الأنسجة ( $p < 0.05$ ) ذلك يمكن اعتبار كثافة الأوعية الدموية في سرطان الثدي من المؤشرات التي قد تساعد في إعطاء صورة عن مستقبل المرض خاصة إذا تم اعتماده بالإضافة إلى المؤشرات المعتمدة الأخرى والتي في مقدمتها مستقبل الاستروجين.

### Abstract

For three years duration (Jan 2009 – Des 2011), 50 cases of ER positive cases and 50 cases of ER negative cases were collected among mastectomy samples from patients with invasive ductal carcinoma of the breast which were received by the department of histopathology in AL-Hilla teaching hospital. microvessel density (MVD) estimation for all cases using CD – 31 & VWF immunostain, and the quantitative analyses of the microvessels in the 10 high power fields revealed the median for vessels count identified by anti-CD31 in ER-positive & ER- negative groups were (18, 30) respectively, while median MVD as it expressed by anti-VWF in ER-positive & ER-negative groups were (19, 33)

respectively. There were greater concentrations of microvessels stained brown by both antibodies (CD31 & VWF) in estrogen receptors- negative group compared to the estrogen receptors – positive group. This difference was statistically significant ( $p < 0.001$ ). The highest values of MVD were obtained using anti-VWF other than anti-CD31 & the median MVD was significantly different between those two antibodies ( $p < 0.005$ ). So the conclusion is that, high vessels count represent increased tumor angiogenesis and correlated with estrogen status, and tumor grade. Microvessels quantitation may be an additional prognostic factor especially when it combined with more established parameters like estrogen receptor status.

### **Introduction**

Angiogenesis is a central part of many normal homeostatic processes & non neoplastic diseases. Regarding malignant neoplasia, it's now evident that tumors have a very limited capacity to grow without vascular support; therefore, formation of blood vasculature is obligatory step to sustain the essential nutrients to the cancer mass.<sup>(1)</sup>

There is considerable experimental evidence showing that tumor growth is dependent on angiogenesis; moreover, a tumor will not grow to more than 1-2mm, around  $10^6$  cells, nor metastasize if neovascularization from preexisting capillaries fail to occur<sup>(2, 3)</sup>.

Thus measurement of vascular growth may be clinically important in breast cancer specimens. The common pathologic approach to assessing angiogenesis involves microscopic estimation of microvessel density on tissues probed for endothelial markers by immunohistochemistry. Several markers of blood endothelium have been developed for routine use, including CD31, CD34, factor VIII- related antigen (Von willebrand factor or VWF)<sup>(4)</sup>.

There has growing interest in the important role played by the estrogen receptor in the clinical care of patients with breast cancer<sup>(5)</sup>. Around 60% of primary breast cancers are estrogen receptor-positive. This possibility makes the definition of ER status a

routine procedure in the management of patients with breast cancer, primarily as a predictive & then as a prognostic factor <sup>(6)</sup>.

A correlation between ER status & microvessel count in a breast tumor would be of great interest, useful not only for defining prognosis but also for selection of patients with initial breast cancer for hormone therapy <sup>(7)</sup>.

In an attempt to further characterize this correlation, the aim of the present study was to evaluate angiogenesis in invasive ductal carcinoma of the breast by the assessment of microvascular density using anti-CD31 & anti-VWF antibodies & its relation to the ER status.

### **Materials and methods**

This study included mastectomy samples from patients with invasive ductal carcinoma of the breast which were received by the department of histopathology at Al - Hilla teaching hospital for the period from January 2009 to December 2011. The biopsy samples were fixed in buffered formalin & stained with hematoxylin & eosin for confirmation of the diagnosis of invasive ductal carcinoma. All samples were then submitted to immunohistochemical analysis to evaluate estrogen receptor status. One hundred cases were selected according to the estrogen receptors status, 50 cases were estrogen positive & the other 50 case were estrogen negative. Scoring of intensity was done according to Allred scoring guideline <sup>(8)</sup> which depend on total scoring for proportion of tumor cells with positive nuclear staining ( proportion score ) plus estimated average of staining intensity for all positive cells( intensity score). With total score range (0, 2-8), a positive result for ER is defined as TS > or = 3.

For identification of blood vessels, representative paraffin embedded sections from each specimen were stained with anti-CD31 (code IR610, ready to use FLEX, Dako) & anti-VWF (code IR527, ready to use, FLEX, Dako). Four mm- thick sections were deparaffinised & rehydrated. Antigen retrieval was achieved by incubating sections in water bath in 95C<sup>o</sup> for 20 min. After blocking of endogenous hydrogen peroxidase & non – specific

reactions; sections were incubated for 30 min with primary antibodies. Visualization of staining was conducted using Envision +kit /HRP, dual link mouse/ rabbit according to manufacturer's instructions. Immunohistochemical reactions were developed with diaminobenzidine as chromogenic peroxidase substrate, sections were counterstained with hematoxylin. Liver hemangiomas were used to test positive and negative controls for the immunohistochemical reaction.

For microvessel density (MVD) estimation, each of the studied slide was first scanned at 100 x magnification, and 10 areas with abundant microvessels were chosen and defined as "hot spot", the number of microvessels in each of these hot spots was determined at 400x magnification using Olympus microscope <sup>(9)</sup>. Blood vessels were identified as a group of brown stained endothelial cells, clearly separated from the adjacent microvessels, tumoral cells & other conjunctive tissues.

### **Statistical analysis**

Three levels of statistics were performed using the SPSS version( 17 )

A. Kruskal –Wallis test used to defined the relationship between MVD as its expressed by CD31 & VWF & the Estrogen receptors status in each group with level of significance of <0.005.

B.Mann- Whitney test non- parameteric test were used to establish homogeneity between the two groups with respect to the grade of differentiation & MVD expression to each markers.

C. Wilcoxon signed ranks test were to compare the median of MVD as expressed by CD31 & VWF.

### **Results**

Clinicopathological parameters of 100 invasive ductal breast carcinoma studied are summarized as follow. Histologic grades included Grade I (n= 13), grade II (n= 61), grade III (n=26), estrogen positive cases (n=50), & estrogen negative cases (n=50).

Quantitative analyses of the microvessels in the 10 fields revealed the median for vessels count identified by anti-CD31 in ER-

positive & ER- negative groups of 18, 30 respectively, & median MVD as it expressed by anti-VWF in ER-positive & ER-negative groups of 19, 33 respectively. There were greater concentrations of microvessels stained brown by both antibodies (CD31 & VWF) in estrogen receptors- negative group compared to the estrogen receptors – positive group (fig 1 & 2). This difference was statistically significant ( $p < 0.001$ ).

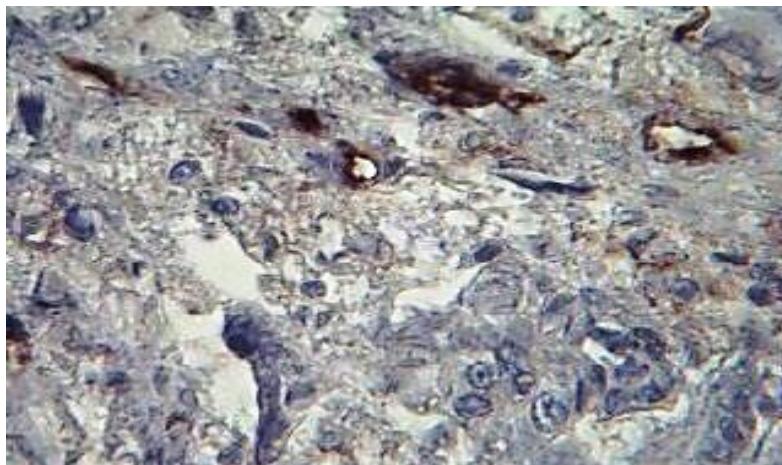
The highest values of MVD were obtained using anti-VWF other than anti-CD31 & the mean MVD was significantly different between antibodies ( $p < 0.005$ ).

Regarding the correlation between tumor grade & MVD as it expressed by anti-CD31 & anti-VWF antibodies in both groups; MVD increased from low to intermediate to high nuclear grades with statistically significant differences ( $p < 0.001$ ) between the grades & MVD. (Tables 1 & 2).

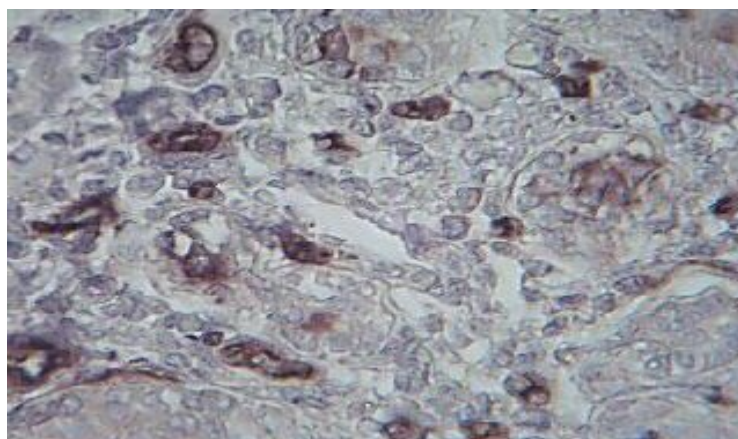
**Table No. (1).The correlation between tumor differentiation of invasive ductal carcinoma & MVD as expressed by median values for anti - CD31 & anti -VWF VIII in estrogen positive cases.**

Grade of tumor differentiation	No. of cases	Median MVD (CD31)	Median MVD (VWF)
Low grade	9	12	13
Intermediate grade	37	18	20
High grade	4	26	31
Total	50		

**Table No. (2).The correlation between tumor differentiation of invasive ductal carcinoma & MVD as expressed by median values for anti - CD31 & anti - VWF VIII in estrogen negative cases.**



**Fig no. 1. show a histological section of estrogen receptor-positive breast carcinoma , showing sparse vessels stained with anti CD31.(original magnification , 400x).**



**Fig no. 2. Show a histological section of estrogen receptor-negative breast carcinoma , showing a high concentration of microvessels stained with anti VWF.(original magnification , 400x).**

Grade of tumor differentiation	No. of cases	Median MVD (CD31)	Median MVD (VWF)
Low grade	4	19	20
Intermediate grade	24	29	31
High grade	22	34	37
Total	50		



## Discussion

The growth and proliferation of tumor cells, as well as their metastatic dissemination, have been shown to be preceded and facilitated by the formation of new blood vessels from preexisting capillaries<sup>(3)</sup>. Angiogenesis has been considered an independent prognostic factor<sup>(10)</sup>, therefore, its assessment may provide additional information on the biological profile of the tumor, and may have applications in prognostic evaluation and as a therapeutic target in human breast carcinoma<sup>(11, 12)</sup>.

the majority of studies have shown that MVD correlates significantly with various pathological & biological features generally associated with more aggressive disease, such as tumor size, nodal status, and histological and/or nuclear grade<sup>(13, 14, 15)</sup>. However the reproducibility of these results has been questioned<sup>(16)</sup>. In addition to the previously mentioned features, although higher density of microvessels is generally found in malignant breast tumors with negative estrogen receptors have a relatively poorer prognosis, conflicting reports have been published on the correlation between tumoral angiogenesis & ER status.<sup>(17,18, 19)</sup>

In the present study, microvessels count as its expressed by anti-VWF & anti CD31 in estrogen negative breast carcinoma was significantly greater compared to estrogen positive breast carcinoma ( $P < 0.001$ ), these findings agreed with other studies<sup>(7, 20, 21)</sup>. The presence of low MVD in ER positive tumors in the present study indicate a correlation between tumor angiogenesis & estrogen receptor status. This correlation supported by in vivo study carried by Ali et al<sup>(18)</sup> who demonstrate that high levels of ER- alpha down regulate angiogenic factors leading to inhibition of tumor angiogenesis.

On the other hand Erdem et al<sup>(19)</sup> failed to show any difference between mean MDV in estrogen receptors –positive & negative tumors.

This study also demonstrate a significant correlation between MVD As its Expressed by anti VWF & Anti CD31 & the tumor grades, the MVD median increased in higher grades of invasive breast carcinoma, these findings supported by other studies<sup>(22,23)</sup>.

This study also highlight that the density of stained microvessels was greater & the staining was more intense with anti -VWF than anti-CD31 in both estrogen negative & estrogen positive cases, these findings agreed with other studies which revealed the same findings<sup>(24, 25)</sup>, however; da Silva demonstrate that there is no significance difference in the MVD which is expressed by both antibodies<sup>(26)</sup>.

In conclusion, the results of our study revealed that high vessels count represent increased tumor angiogenesis and correlated with ER status and tumor grade. Microvessels quantitation may be an additional prognostic factor especially when it combined with more established parameters like estrogen receptor status, can help in choosing appropriate patient management & the patients could get benefits from tumor vasculature –directed therapy and hormonal treatment.

## References

1. Kerbel R. s. tumor angiogenesis, *The New England journal of Medicine*. 2008,358,19: 2039-2049.
2. Liotta L A, Kleinerman J, Saidel GM. Quantitative relationships of intravascular tumor cells, tumor vessels and pulmonary metastasis following tumor implantation. *Cancer Res*.1989,34: 997-1004.
3. Folkman J. Angiogenesis in cancer, vascular, rheumatoid and other disease. *Nat. Med*. 1995,1:27-31.
4. Uzzan B, Nicolas P, Cucherat M, et al. Microvessel density as a prognostic factor in women with breast cancer: a systemic review of the literature and meta-analysis. *Cancer Res*. 2004, 64: 2941-2955.
5. Hanstein B, Djahasouzi S, Dall P, et al. Insights into the molecular biology of estrogen receptor define novel therapeutics targets for breast cancer. *Eur. J Endocrinol*. 2004, 150: 243-255.
6. Fitzgibbons P L, Page DL, Weaver D, et al. Prognostic factors in breast cancer. *College of American pathologists consensus statement. Arch path Lab Med*. 1999,124:966-978.



7. Vamesu S. angiogenesis and ER/PR status in primary breast cancer patients: An analysis of 158 needle core biopsies. *Rom J morphol Embryol.* 2007, 148: 25-31.
8. Allred DC, Harvey JM, Berardo M, et al. Prognostic and predictive factors in breast cancer by immunohistochemical analysis. *Mod Pathol.* 1998, 11: 155-168.
9. Weidner N. Quantification of angiogenesis in solid human tumors: An international consensus on the methodology and criteria of evaluation. *Eur j of cancer.* 1996, 32(A): 2474-2484.
10. Folkman J. seminars in medicine of Beth Israel hospital, Boston. Clinical applications of research on angiogenesis. *N Engl. J Med.* 1995, 333: 1757-1763.
11. Bottini A, Berruti A, Bersiga A, et al. Changes in microvessls density as assessed by CD34 antibodies after primary chemotherapy in human breast cancer. *Clin Cancer Res.* 2002, 8:1816-1821.
12. Da Silva BB, da Silva Junior RG, Borges US, et al. Quantification of angiogenesis induced in Rabbit cornea by breast carcinoma of women treated with tamoxifen. *J Surg Oncol.* 2005, 90: 77-80.
13. Weidner N, Folkman J, Pozza F, et al. Tumor angiogenesis: a new significant and independent prognostic indicator in early stage breast carcinoma. *J Natl Cancer Inst.* 1992, 84: 1875-1887.
14. Gasparini G, Weidner N, Bevilacqua P, et al. Tumor microvessel density, P53 expression, tumor size & peritumoral lymphatic vessels invasion are relevant prognostic markers in node- negative breast carcinoma. *J Clin Oncol.* 1994, 12: 454- 466.
15. Heimann R, Ferguson D, Power C, et al. Angiogenesis as a predictor of long term survival for patients with node negative breast cancer. *J Natl Cancer Inst.* 1996,88: 1764-1769.
16. Vermulen P.B, Libura J, Libura M, et al. Tumor angiogenesis as a prognostic assay for invasive ductal breast carcinoma. *J Natl Cancer Inst.* 1995, 87:1797-1802.
17. Augustin HG. Antiangiogenic tumor therapy: will it work? *Trends Pharmacol Sci.* 1998, 19: 216-222.

18. Ali SH, Odonnell AL, Balu D, et al. Estrogen receptor alpha in the inhibition of cancer growth and angiogenesis. *Cancer Res.* 2000, 60: 7094-7098.
19. Erdem O, Dursun A, Coskun U, et al. The prognostic value of P53 and c-erb-B2 expression, proliferative activity & angiogenesis in node- negative breast carcinoma. *Tumori.* 2005, 91:6-52.
20. J B Parentes, P v lopes- Costa, C G Pires, et al. Quantitation of angiogenesis in estrogen receptors positive & negative breast carcinoma. *Int Semin Surg Oncology.* 2007; 4: 22-27.
21. Vamesu S. Angiogenesis and co –expressed of ER and c-erb-B2 protein in primary breast cancer patients: an analysis of 158 needle core biopsies. *Rom J Morphol Embryol.* 2008; 49(4): 25-31.
22. Silvano B, Arthur K,C, Lee MBBS, Ronald A, et al. microvessel quantitation and prognosis in invasive breast carcinoma. *Human path.* 1992; 23: 755-761.
23. Vamesu S. Angiogenesis and tumor grading in primary breast cancer patients: analysis of 158 needle core biopsies. *Rom J Morphol Embryol.* 2006; 47(3): 251-257.
24. Leek RD. The prognostic role of angiogenesis in breast cancer. *Anti cancer Res,* 2001; 21(6B): 4325-4331.
25. Teo NB, Shoker BS, Jarvis C, et al. Vascular density And phenotype around ductal carcinoma in situ ( DCIS) of the breast. *British J of Cancer.* 2002; 86: 905-911.
26. Da Silva BB, Lopes –Costa PV, Dossantos AR, et al. comparison of three vascular endothelial markers in the evaluation of microvessel density in breast cancer. *Eur J Gynaecol Oncol.* 2009; 30(3): 285-288.