

Efficacy of oral mefenamic acid in treatment of rash of Gianotti–Crosti syndrome: A prospective noncontrolled case-series study

Usama Abdul-Jaleel*

الخلاصة

متلازمة جيانوتي كروستي هي استجابة جلديه متميزه لالتهابات فايروسية وغير فايروسية تصيب في الغالب الاطفال. لا يوجد علاج حالياً لتقليل مدة المرض التي تستمر 3-8 اسابيع. مفيناميك اسيد هو احد مضادات الالتهاب غير الستيرويديه التي تعمل كمثبطات تنافسيه للخليق البايولوجي للبروستاغلاندين. تقييم فعالية مفيناميك اسيد 50 ملغم في علاج متلازمه جيانوتي كروستي. اشتملت هذه الدراسة على 36 مريض مصاباً بمتلازمة جيانوتي كروستي حيث تم تشخيصهم من قبل اختصاصي الجلديه العياده الاستشارية في مستشفى الديوانية التعليمي في المده من كانون الثاني 2012 إلى اذار 2013, و تم إعطاؤهم علاج مفيناميك اسيد فموياً بجرعة 50 ملغم مرتين يومياً لمدة 10 ايام وتم تسجيل كل المعلومات الخاصة بكل مريض حيث تم متابعة الأعراض والعلامات على المرضى في كل زيارة. اظهر تحليل البيانات تأثيراً ذا قيمة واضحة لعلاج مفيناميك اسيد فموياً في تحسين العلامات والأعراض والتي تشمل الطفح, و الاحمرار بعد 10 ايام من العلاج ولم تسجل ايه تأثيرات جانبية للدواء اثناء العلاج وفي فتره المتابعه. في ضوء النتائج التي أفرزتها هذه الدراسة يمكننا استنتاج ما يلي: قد يكون مفيناميك اسيد 50 ملغم فعالاً في علاج علامات الطفح المرتبطة بمتلازمة جيانوتي كروستي.

Abstract

Background: Gianotti–Crosti syndrome (GCS) is a characteristic cutaneous response to viral & non-viral infection mainly affecting children. No treatment appears to shorten the course of the disease which lasts 3-8 weeks. Mefenamic acid is NSAID which acts as competitive inhibitor of prostaglandin biosynthesis.

Objective: To assess the efficacy and safety of oral mefenamic acid 50 mg twice a day in the treatment of (GCS) for 10 days

Methods : In this prospective non-controlled case series study, 36 patients were identified as having Gianotti–Crosti syndrome by dermatologist in Al-Diwanyia Teaching Hospital, from January 2012 to May 2013 and they have been treated with oral mefenamic acid 50 mg twice a day for 10 days.

*Department of Dermatology, Al-Qadisiya College of Medicine Al-Diwanyia, Iraq.

Results : 36 patients entered the current study. The mean age of the patients was 2 ± 1.2 (1 - 5.5) years. There were 19 (52.8 %) females and 17(47.2 %) males. Complete clearance of the rash of GCS at all sites was seen in 33 patients (91.6 %) within 10 days of initiation of the therapy, leaving the the skin with fine desquamation ($P < 0.05$) .Two patients experienced no change in the rash until after 3 weeks it got resolution of the rash and one patient get his rash resolved after one month. None of the patients suffered adverse effects during the usage of treatment and the period of the follow-up.

Conclusion : oral mefenamic acid seems to be effective in treatment of **Gianotti–Crosti syndrome**

Key words : Gianotti–Crosti syndrome, mefenamic acid

Introduction

Gianotti–Crosti syndrome is a characteristic cutaneous response to viral infection^(1,2,3). The majority of the earliest reported cases had hepatitis B infection, but several other viruses and even non-viral infections have been associated. The most common of these is EBV^(4,5). Infrequently reported, and therefore of less certain significance, are coxsackie A16⁽⁶⁾, coxsackie B4 and B5 [5], echovirus 7⁽⁷⁾, echovirus 9⁽⁸⁾, poliovirus⁽⁹⁾, CMV⁽⁵⁾, HHV6⁽¹⁰⁾, respiratory syncytial virus⁽⁹⁾, parainfluenza virus⁽³⁾, hepatitis A⁽¹¹⁾, parvovirus B19⁽⁸⁾, milker's nodules⁽¹³⁾ and HIV⁽¹⁴⁾. Non-viral associations are Mycoplasma pneumoniae and β -haemolytic streptococci^(9,15). Occasional cases following immunization, for example combined measles, mumps, rubella vaccine⁽¹⁶⁾, diphtheria, pertussis and influenza^(5,17) and hepatitis A⁽¹⁸⁾ or B⁽¹⁹⁾ are of uncertain significance. In a minority of cases, no evidence of viral infection can be found. The syndrome mainly affects children between the ages of 6 months and 12 years, though occasional adult female cases have occurred^{20,21)}.
.Pathology : The skin lesions show slight or moderate acanthosis and hyperkeratosis. In the edematous upper dermis an infiltrate of lymphocytes and histiocytes surrounds dilated capillaries. The lymph nodes show a diffuse reticulum-cell

hyperplasia, often of severe degree. Clinical features^(1,22). Over the course of 3 or 4 days a profuse eruption of dull red flat-topped papules develops first on the thighs and buttocks, then on the extensor aspects of the arms, and finally on the face. In the hepatitis B cases, liver involvement appears to be invariable, usually mild and anicteric, but occasionally there is jaundice, and histological recovery may take between 6 months and 4 years.

Treatment: There is no specific treatment. Emollients and topical steroids may help to relieve pruritus. However, spontaneous resolution usually occurs within 3–8 weeks⁽²⁴⁾. No treatment appears to shorten the course of the disease⁽²⁵⁾.

Mefenamic acid is a non-steroidal anti-inflammatory drug which is a competitive inhibitor of COX-1 and COX-2, which are responsible for the first committed step in prostaglandin biosynthesis. Decreasing the activity of these enzymes thus reduces the production of prostaglandins, which are implicated in the inflammation process.

Aim of the study

To assess the efficacy and safety of oral mefenamic acid 50 mg twice a day in the treatment of Gianotti–Crosti syndrome.

Patients and methods

Study design:

Open labeled (prospective uncontrolled) therapeutic trial was done on 36 outpatients seeking treatment for Gianotti–Crosti syndrome were assessed by dermatologist in the outpatient clinic of the Department of Dermatology in Al-Diwanyia Teaching Hospital, Diwanyia, Iraq, from January 2012 to May 2013. This study was in agreement with the ethics of Al-Diwanyia Teaching Hospital.

Patients

The patients were diagnosed clinically by a dermatologist in Al-Diwanyia Teaching Hospital as Gianotti–Crosti syndrome. Questions covered age, sex, All patients started on oral mefenamic acid 50 mg twice daily for 10 days.

Evaluations

Evaluation of clinical symptoms and complaints pretreatment and after initiation of treatment with oral mefenamic acid

The evaluation was performed by same dermatologist at day 0 , 10 and 30 after the initiation of the treatment with oral mefenamic acid.

Results

36 patients entered the current study. The mean age of the patients was 2 ± 1.2 (1-5) years. There were 19 (52.8 %) females and 17 (47.2 %) males.

All the patients complained of pruritus but with variable severity . Figure(1) and(2) showed that treatment with oral mefenamic acid had lead to cause complete clearance of the rash of GC at all sites in 33 patients (91.6 %) within 10 days of initiation of the therapy, leaving the the skin with fine desquamation ($P < 0.05$). Two patients experienced no change in the rash until after 3 weeks it got resolution of the rash and one patient get his rash resolved after one month . Subsequent follow-up to 8 weeks did not show any recurrence of the rash. None of the patients noticed adverse effects during the usage of treatment and the period of the follow-up.

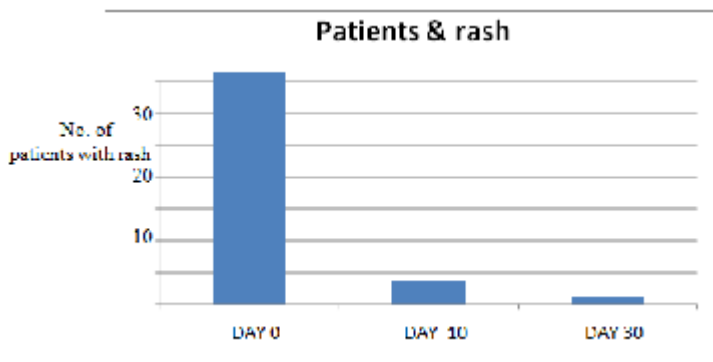


Fig .(1) The effects of mefenamic acid 50mg twice daily (in day 0, day, 10 day 30) on the number patients with rash of Gianotti–Crosti syndrome.

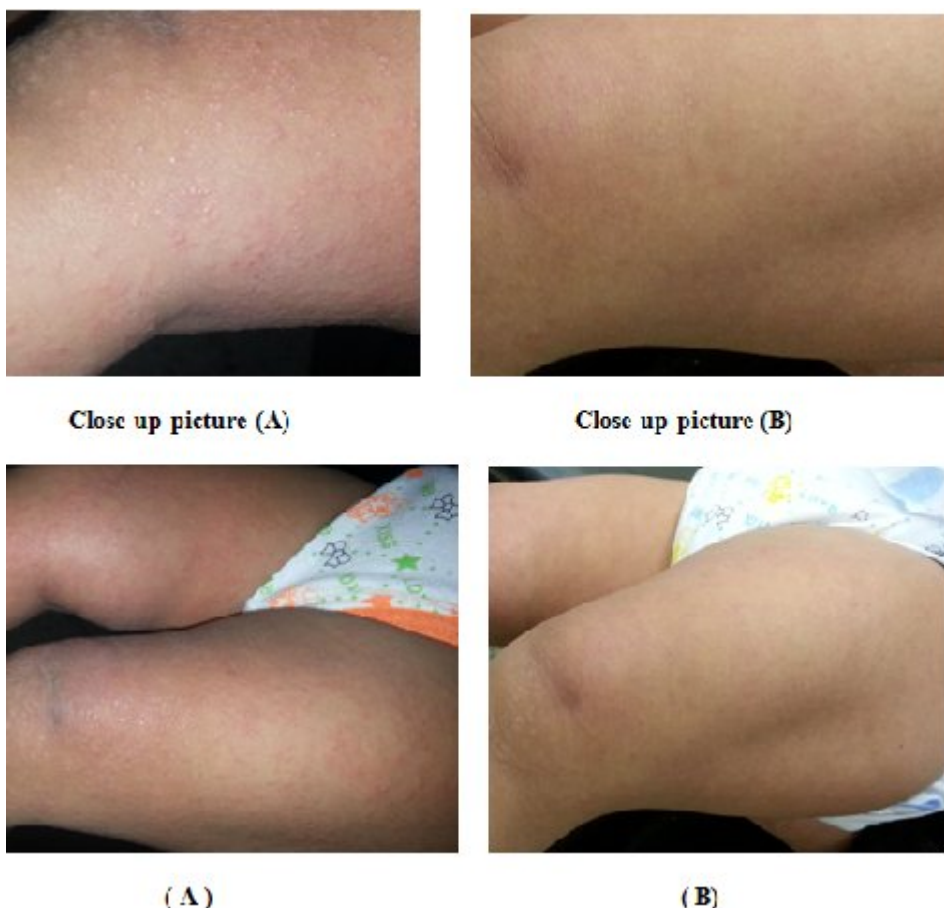


Fig. (2) showed patient with Gianotti–Crosti syndrome before treatment (A) and after 10 days treatment with mefenamic acid (B)

Discussion

Although the treatment for Gianotti–Crosti syndrome is supportive and the prognosis is good with spontaneous resolution , it usually takes 3-4 weeks and may persist for up to 8 weeks⁽²⁴⁾ , .Taking in consideration that the parents got concerned about this "unusually prolonged symptomatic rash" .No treatment appears to shorten the course of the disease⁽²⁵⁾ . Mefenamic acid is a non-steroidal anti-inflammatory drug which is a competitive inhibitor of COX-1 and COX-2, which are responsible for the first committed step in prostaglandin biosynthesis.

In the current study, the results showed that mefenamic acid might be able to shorten the course of the rash of the disease .Clearance

of the rash can not be attributed to the natural history of the disease especially when the majority of the patients had got improved within approximately equal time i.e. 10 days. The rash of this disease usually takes variably prolonged duration. The mechanism of action of this drug is unknown and probably through its anti-inflammatory effect and we recommend to search for its effect through a further proper study.

Conclusions

From this study, one can conclude that mefenamic acid therapy in oral form may be able to shorten the course of the rash the disease.

Drawbacks of this study were. (1) Lack of a control group, (2) the study did not reveal the mechanism by which mefenamic acid affected the rash (3) Limited follow-up of the patients.

References

- 1 Brandt O, Abeck D, Gianotti R et al. Gianotti–Crosti syndrome. *J Am Acad Dermatol* 2006; 54: 136–45.
- 2 Crosti A, Gianotti F. Dermatose eruptive acro-situee d'origine probablement virosique. *Dermatologica* 1957; 115: 671–7.
- 3 Spear KL, Winkelmann RK. Gianotti–Crosti syndrome. A review of ten cases not associated with hepatitis B. *Arch Dermatol* 1984; 120: 891–6.
- 4 Drago F, Crovato F, Rebora A. Gianotti–Crosti syndrome as a presenting sign of EBV-induced acute infectious mononucleosis. *Clin Exp Dermatol* 1997; 22:301–2.
- 5 Taieb A, Plantin P, Du Pasquier P et al. Gianotti–Crosti syndrome: a study of 26 cases. *Br J Dermatol* 1986; 115: 49–59.
- 6 James WD, Odom RB, Hatch MH. Gianotti–Crosti-like eruption associated with coxsackievirus A-16 infection. *J Am Acad Dermatol* 1982; 6: 862–6.
- 7 Labbe A, Peyrot J, Goumy P et al. Syndrome acropapulovesiculeux de l'enfant quatre observations d'etiologie virale probable. *Pediatric* 1982; 37: 467–71.

- 8 Rogers S, Connolly JH. Letter: Gianotti–Crosti syndrome and viral infection. *BMJ* 1974; 4: 529.
- 9 Draelos ZK, Hansen RC, James WD. Gianotti–Crosti syndrome associated with infections other than hepatitis B. *JAMA* 1986; 256: 2386–8.
- 10 Chuh AA, Chan HH, Chiu SS et al. A prospective case control study of the association of Gianotti–Crosti syndrome with human herpesvirus 6 and human herpesvirus 7 infections. *Pediatr Dermatol* 2002; 19: 492–7.
- 11 Sagi EF, Linder N, Shouval D. Papular acrodermatitis of childhood associated with hepatitis A virus infection. *Pediatr Dermatol* 1985; 3: 31–3.
- 12 Borreda D, Palomera S, Gilbert B et al. A propos de vingt-quatre observations d'infections à parvovirus humain B19 chez l'enfant. *Ann Pediatr (Paris)* 1992; 39:543–9.
- 13 de la Torre C. Gianotti–Crosti syndrome following milkers' nodules. *Cutis* 2004; 74: 316–8.
- 14 Blauvelt A, Turner ML. Gianotti–Crosti syndrome and human immunodeficiency virus infection. *Arch Dermatol* 1994; 130: 481–3.
- 15 Manoharan S, Muir J, Williamson R. Gianotti–Crosti syndrome in an adult following recent *Mycoplasma pneumoniae* infection. *Australas J Dermatol* 2005; 46: 106–9.
- 16 Velangi SS, Tidman MJ. Gianotti–Crosti syndrome after measles, mumps and rubella vaccination. *Br J Dermatol* 1998; 139: 1122–3.
- 17 Cambiaghi S, Scarabelli G, Pistritto G et al. Gianotti–Crosti syndrome in an adult after influenza virus vaccination. *Dermatology* 1995; 191: 340–1.
- 18 Monastirli A, Varvarigou A, Pasmazi E et al. Gianotti–Crosti syndrome after hepatitis A vaccination. *Acta Derm Venereol* 2007; 87: 174–5.
- 19 Karakas M, Durdu M, Tuncer I et al. Gianotti–Crosti syndrome in a child following hepatitis B virus vaccination. *J Dermatol* 2007; 34: 117–20.

- 20 Ting PT, Barankin B, Dytoc MT. Gianotti–Crosti syndrome in two adult patients. *J Cutan Med Surg* 2008; 12: 121–5.
- 21 Gibbs S, Burrows N. Gianotti–Crosti syndrome in two unrelated adults. *Clin Exp Dermatol* 2000; 25: 594–6.
- 22 Boeck K, Mempel M, Schmidt T et al. Gianotti–Crosti syndrome: clinical, sero-logic, and therapeutic data from nine children. *Cutis* 1998; 62: 271–4.
- 23 Gianotti-crosti syndrome. In: Tony B, Stephen B, Neil C, Christopher G, editors. *Rooks Textbook of Dermatology*. Wiley Blackwell; eighth edition 2010. pp1353-1354
- 24 Gianotti-crosti syndrome. In: Jean L. Bologna, Joseph L. Jorrizo, Julie V. Schaffer, editors. *Dermatology*. Elsevier Saunders ; third edition 2012. pp33.77-33.78
- 25 Gianotti-crosti syndrome. In: William D. James, Timothy G. Berger, Dirk M. Elston, editors. *Andrews diseases of the skin: clinical dermatology*: Elsevier Saunders ; eleventh edition 2011. pp 382.