

## PCNL under Ultrasound Guidance only in Al Diwaniya Teaching Hospital

Ali Hamdan Fahad, college of medicine, University of Al-Qadisiyah.

### الخلاصة

#### الخلفية العلمية:

حصى المسالك البولية تعد واحده من المشاكل الصحية الأساسية الشائعة. وعملية استخراج حصاة الكلى عن طريق الجلد هي من العمليات المفضلة لاستخراج حصاة الكلى الكبيرة، الحصاة الموجودة في الجزء الأسفل من الكلى وكذلك الحصاة التي فشلت في الاستجابة لوسائل العلاج الأقل تداخلا جراحيا. وقد أجرينا هذه الدراسة على عملية استخراج حصاة الكلى بالناظور عن طريق الجلد بمساعدة السونار لعلاج حصاة الكلى.

#### هدف الدراسة:

لدراسة فعالية وسلامة عملية استخراج حصاة الكلى بالناظور بمساعدة السونار.

#### منهج الدراسة:

شملت الدراسة 100 مريض (62 من الذكور و38 من الإناث) من المصابين بحصى الكلى في مستشفى الديوانية التعليمي قسم المسالك البولية. بدأت هذه الدراسة من تشرين الأول 2013 إلى تشرين الأول 2015، تم تقييم جميع المرضى عن طرق اخذ المعلومات الطبية الكاملة، والفحص السريري، التحليلات المختبرية، والسونار والمفراس الشعاعي. وتم معرفة خصائص الحصى المتعلقة بمكانها، حجمها، وموقعها ثم استخراج الحصى بالناظور عن طريق الجلد بمساعدة السونار

#### النتائج:

كشفت الدراسة أن الدخول على منتصف الكلى كان الأكثر شيوعا (73%). إزالة حصاة الكلى نهائيا كان (84%)، وباستخدام وسائل علاجية أخرى، تم الحصول على نسبة (100%). وكان متوسط وقت العملية  $71 \pm 7.4$  (45-110) دقيقة. كانت الإقامة في المستشفى بمتوسط  $3 \pm 0.2$  (2-5) أيام. ومن دون وجود أي مضاعفات خطيرة خلال فترة الدراسة.

#### الاستنتاجات:

ان عملية استخراج حصاة الكلى عن طريق الجلد بمساعد السونار هي من العمليات الفعالة والأمنة والمفضلة على استخراجها بواسطة الناظور بمساعدة الفلوروسكوب، ونصح باجراها بهذه الطريقة في بقية المستشفيات.

### ABSTRACT

**Background:** Urinary stone disease is a major health care problem due to its high prevalence and incidence. Percutaneous Nephrolithotomy (PCNL) is the preferred approach to large stones, stones in the lower pole, or stones that are resistant to less invasive technology. Fluoroscopy is commonly used imaging technique during PCNL. We evaluated the safety and efficacy of ultrasound guided PCNL for treatment of renal stones.

**Aim of the study:** to assess the safety and efficacy of ultrasound guided, as an alternative to radiographic guided, percutaneous nephrolithotomy in Al Diwaniyah Teaching Hospital.

**Patients & Methods:** 100 patients (62 males and 38 females) with renal stones were admitted to Al Diwaniya Teaching Hospital, urology unit were enrolled in this study From October 2013 to October 2015 All patients were evaluated by history, physical examination, laboratory investigation. The stone size, site, side, opacity and degree of obstruction were assessed by preoperative radiographic imaging studies,

including IVU, ultrasound and computerized tomography (CT scan). PCNL has been performed under ultrasound guidance.

**Results:** The study revealed that the mid pole calyx was most commonly punctured (73%). Complete stone clearance was (84%). The average operative time was  $71 \pm 7.4$  (45–110) minutes. The mean hospital stay was  $3 \pm 0.2$  (2-5) days. With dual therapy (PCNL + ESWL/URS), stone clearance was (100%). No serious complications were encountered during the study.

**Conclusion:** PCNL under ultrasonography guide is an effective and safe method for renal stone treatment and is preferably replaced PCNL under fluoroscopic guidance.

**KEY WORDS:** Ultrasonography, Percutaneous Nephrolithotomy (PCNL), Renal Stone, Staghorn Stone, Flouroscopy.

## INTRODUCTION

Urinary stone disease is a major health care problem due to its high prevalence and incidence. The disease is very common among both men and women; stones form twice as often in men as in women, with an estimated prevalence among the population of 2-3% and an estimated lifetime risk of 12% for white males and 5–6% for white females. <sup>(1)</sup>

The treatment options for stone disease are watchful waiting, medical dissolution therapy, ESWL, flexible ureteroscopy, PCNL, and open surgery. <sup>(2)</sup>

The first description of percutaneous stone removal was that of Rupel and Brown (1941), who removed a stone through a previously established surgical nephrostomy. It was not until 1955, however, that Goodwin and associates described the first placement of a percutaneous nephrostomy tube to drain a grossly hydronephrotic kidney. These researchers did not have the benefit of radiographic guidance, and so the drainage tube was placed without imaging. In 1976, Fernstrom and Johansson first reported the establishment of percutaneous access with the specific intention of removing a

renal stone. Subsequent advances in endoscopes, imaging equipment, and intracorporeal lithotripters allowed urologists and radiologists to refine these percutaneous techniques through the late 1970s and early 1980s into well-established methods for removal of upper urinary tract calculi. <sup>(3)</sup>

Since its first introduction in 1976 by Fernstorm and his colleagues, there have been many improvements in the technique and equipment of percutaneous nephrolithotomy in the next three decades, which have made percutaneous nephrolithotomy (PCNL) an accepted management option for urolithiasis. <sup>(4, 5)</sup>

The advantages of PCNL over open surgery are:

- 1- Less blood loss.
- 2- Less postoperative pain.
- 3- Fewer wound complications.
- 4- Less effect on renal function.
- 5- Shorter hospital stay.
- 6- Shorter recovery time with early resumption of daily routine work.
- 7- Cosmetically better. <sup>(6)</sup>

After an initial learning phase, a good success rate can be achieved for PCNL (ultimately more than 90%). This high success rate is attributable to more experience, advances in endoscopic

equipment, and advanced devices for destruction of stones. <sup>(7)</sup>

Now, PCNL is the preferred approach for treating large stones, stones in the lower pole, or stones that are resistant to less invasive technology. <sup>(8)</sup>

The key requisite of any percutaneous nephrolithotomy (PCNL) technique is proper access to the collecting system. The ideal puncture would be to develop a percutaneous tract that leads straight from the skin through a papilla and the target calyx into the renal pelvis. This is a basis for any percutaneous renal procedure. <sup>(9)</sup>

Traditionally, PCNL has been performed under fluoroscopy guidance, which exposes patients, surgical staff and theatre staff to the hazards of ionizing x-ray radiation, which are not radiation-dose dependent. <sup>(10)</sup> Although surgical and theatre staff can wear protective aprons, which are bothersome and do not provide complete protection. <sup>(11)</sup>

There has been a recent interest in many centers to use ultrasound as an alternative for fluoroscopy to puncture the pelvicaliceal system during PCNL and find the residual fragments during the procedure. Ultrasound guided PCNL has a definite advantages over fluoroscopy guided PCNL. There is no need for intravenous or retrograde administration of contrast dye; no radiation exposure of the surgical or theatre staff and it provides continuous real time control during puncture with accurate location of radiolucent stones. <sup>(12)</sup>

It provides a three-dimensional picture during puncture while fluoroscopy provides only a two-dimensional picture. It also provides accurate imaging of all tissues/viscera

like intestines and lungs along an intended nephrostomy tract, which is possible only under ultrasound guidance. Similarly, imaging in numerous planes is possible simply by shifting, tilting and rotating the scanning head. <sup>(13)</sup> Since the kidney has a high degree of intrarenal vascular network, the use of real time sonography can be used as a tool for localization of intrarenal vessels and avoidance of puncture by needle, thus reducing the risk of intraoperative and postoperative bleeding. <sup>(14)</sup>

#### **AIM OF THE STUDY**

We aimed in this study to assess the safety and efficacy of ultrasound guided, as an alternative to radiographic guided, percutaneous nephrolithotomy in Al Diwaniyah Teaching Hospital.

#### **PATIENTS AND METHODS**

From October 2013 to October 2015, 100 patients (62 males and 38 females) with renal stones who had been admitted to the urology unit of Al Diwaniyah Teaching Hospital, were enrolled in this study. Their ages ranged from 10 to 60 years with a mean age of  $35 \pm 4$  years. The patients were selected on the basis of standard indications for PCNL for renal stone.

Informed consent was obtained from the patients or relatives before the operation. Patient evaluation was on the basis of medical history, physical examination, laboratory investigations (including urinalysis, full blood count and renal function tests). The stone size, site, side, opacity and degree of obstruction were assessed by preoperative radiographic imaging studies, including IVU, ultrasound and computerized tomography (CT scan).

Topographically speaking, the stones were divided into pelvic and non-pelvic stones. Pelvic stones were found in (76) patients, which were either solitary stones found in (26) patients or staghorn stones in (50) patients. The staghorn stones were further divided into complete staghorn stones (that fill all the pelvicalyceal system) in (9) patients or partial staghorn stones (that extended to one of the calyces) in (41) patients.

On the other hand, the non-pelvic stones were located in the upper calyces in (5) patients and in the middle calyces in (7) patients and located in the lower calyces in the remainder (12) patients.

The mean calculi sizes was 3.152 cm (range from 2.1cm to 5.1 cm). In (85) patients, the stones were radiopaque while in (15) patients they were radiolucent.

All patients received a single dose of a broad-spectrum parenteral antibiotic at the time of induction of anesthesia.

Our equipment were:

- 1- Ultrasound system 3.5 MHz probe , Philips
- 2- Nephrostomy set (9, 12 and 14 Fr.).
- 3- Rigid nephroscope (Storz) 26 Fr. Five-degree Lens.
- 4- Alken dilator up to 30 Fr.
- 5- Working sheath 30 Fr.
- 6- Lithotripter Swiss Pneumatic Lithoclast.
- 7- Grasper for stone fragments removal.
- 8- Normal saline for irrigation.
- 9- Camera and video system.

(Fig. 1, 2)

Anesthetized patients were put in the supine position and a 10-16 Fr. Foley's catheter was inserted into the bladder to provide drainage during the procedure. Patients then were turned to the prone

position with one bolster below the lower chest and another below the lower abdomen.

After standard preparation and draping, identification of the pelvicalyceal system and location of the stone was done by the use of ultrasound using 3.5 MHz probe in the prone position. (Fig. 3)

Percutaneous access into the desired calyx was made with an 18-G diamond tip needle under ultrasonic guidance, and a 0.038 inches J-tipped guide wire was passed and the length of the needle from the skin to the pelvicalyceal system was measured to set the proper length of the dilators to be inserted. (Fig. 4).

A 1-cm skin incision was then made and dilatation of the percutaneous tract was serially performed with metallic Alken dilators over the guide wire and under ultrasonic guidance up to 30-Fr.

Finally, a 30-Fr. working sheath was advanced into the collecting system over the last Alken dilators.

A rigid nephroscope (Storz) 26-Fr. was used in all cases for visualization and extraction of stones and lithotripsy was performed by Swiss Pneumatic Lithoclast.

In some cases, (large staghorn stones), more than one track was needed to ensure stone clearance. Stone clearance was ensured by ultrasound guidance.

After removal of the working sheath, a 16-Fr. nephrostomy tube was placed, and the incision was sutured with a 0-silk suture to control subcutaneous bleeding.

Postoperatively, all patients received standard doses of analgesics and antibiotics for the first 24 hours, then analgesia on demand basis. The bladder catheters were removed the next day if hematuria was not evident. KUB and

nephrostography were performed on the first or second postoperative day to confirm stone clearance and ureteral patency. If residual stone fragments were larger than 5 mm, they were considered significant and were treated with ESWL usually within one month after the procedure. In the absence of

complications, patient were discharged on the second or third postoperative day. On follow-up visits, at 1 and 3 months, urinalysis, serum creatinine, and abdominal ultrasound were performed. Stone recurrence was managed according to the stone size and site.

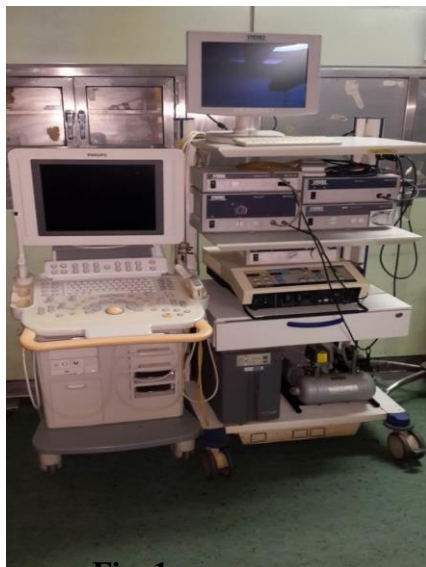

Fig. 1

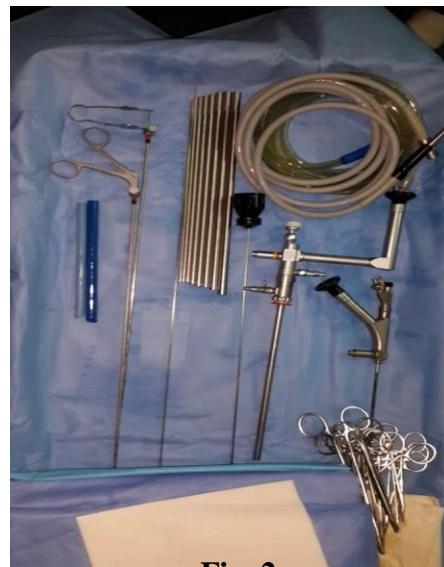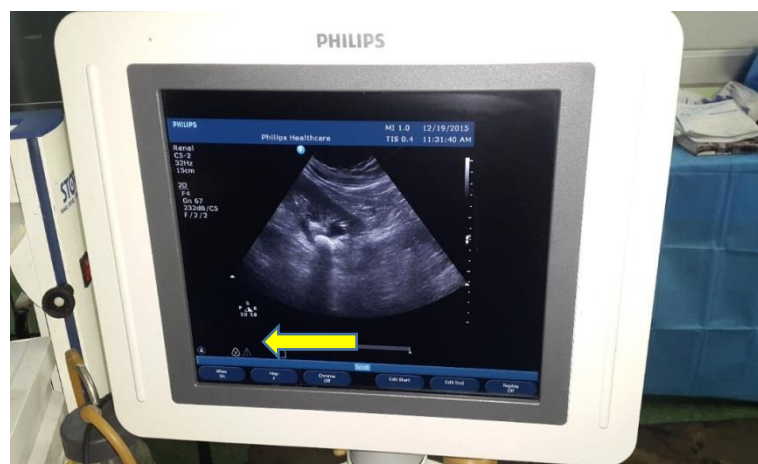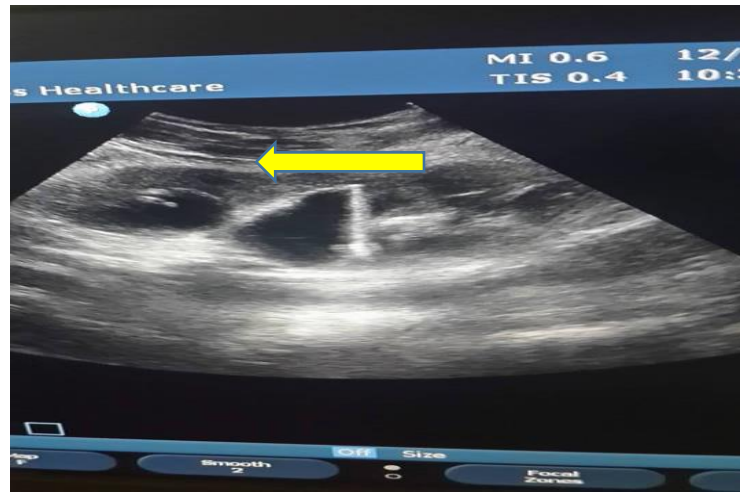


Fig. 2

Equipment used in the procedure.



**Fig. 3:** identification of the pelvicaliceal system and location of the stone by ultrasound.



**Fig. 4:** Percutaneous access into the desired calyx with 18 G diamond tip needle.

## RESULTS

Out of (100) patients, (62%) were male and (38%) female. The mean age of the patients was  $35 \pm 4$  (with a range of 10-60) years and the most common age range affected by stone is the thirties. (Table 1)

The parameters of treated stones in our patients were illustrated in (table 2, 3).

The lower pole calyx was punctured in (13%) patients, middle calyx in (73%) patients and upper pole calyx in (18%) patients.

Complete stone clearance was achieved in (84%) patients, while (16) patients (16%) had residual fragments. In (6) out of (16) patients (37.5%) the residual stone fragments were  $< 5$ mm and passed spontaneously or with the aid of medical expulsive therapy, and in the remaining (10) patients (62.5%), the residual stone fragments ranged from 6-10 mm. ESWL cleared the fragments in 8 patients out of those, while URS and LASER lithotripsy were needed in the other 2 patients. The relations between

the residual stone and stone site and size are illustrated in Table (4).

The average operative time was  $71 \pm 7.4$  (45–110) minutes. The mean hospital stay was  $3 \pm 0.2$  (2-5) days and a nephrostomy tube was kept for (1-3) days.

No serious complications were encountered during the study. Intraoperative bleeding occurred in one (1%) of patients and we continued the procedure with a blood transfusion.

Postoperative fever (temperature  $\leq 37.8$  C) occurred in nine (9%) patients, which settled down with antipyretics and routine antibiotics. Postoperative ureteric colic occurred in (7%) patients, possibly due to the passage of stone fragments that were treated with nonsteroidal anti-inflammatory drugs. Urinary leakage after removal of nephrostomy tube occurred in (9%) of patients, which ceased with conservative treatment. No visceral injury was encountered. All the above-mentioned complications occurred in 15 patients.

Table (1): Age and gender of the patients.

Age group (years)		NO.	%
10-20		9	9%
21-30		28	28%
31-40		36	36%
41-50		20	20%
51-60		7	7%
Mean $\pm$ SD (35 $\pm$ 4)			
Gender	Male	62	62%
	Female	38	38%

Table (2): Parameters of the treated stones:

Parameters		NO.	%
Stone Size	$\leq$ 3cm	73	73%
	> 3cm	27	27%
Mean $\pm$ SD (3.0 $\pm$ 0.4)cm			
Stone Side	Left	35	35%
	Right	65	65%

Table (3): Parameters of the stone site:

Parameters			NO.	%
Pelvic stone	solitary		26	26%
	staghorn	partial	41	41%
		complete	9	9%
Non pelvis stone	Upper pole		5	5%
	Mid pole		7	7%
	Lower pole		12	12%

Table (4): residual stone and stone burden

Parameters		Stone free	residual	Total	p-value
Stone site	Upper	5	0	5	0.61
	Mid	6	1	7	
	lower	11	1	12	
	Pelvic (solitary)	23	3	26	
	Pelvic (staghorn)	39	11	50	
Stone Size	$\leq$ 3cm	67	6	73	0.001
	> 3cm	17	10	27	

## DISCUSSION

Today, open surgery is one of the least common management options for stone disease, and extracorporeal shock wave lithotripsy (ESWL) and endourological procedures, such as uretero-renaloscopic stone removal (URS), and PCNL, are more common modalities to deal with renal stones. <sup>(15)</sup> In the modern era of endourology, open stone surgery is only recommended in patients with severely distorted intrarenal anatomy. <sup>(16)</sup>

Synder and his colleagues compared the success rate, procedure duration, complications, and recovery time for percutaneous and antroptic nephrolithotomy in patients with staghorn stones. They demonstrated a decreased cost, earlier return to activity, decreased requirement for either blood transfusion or narcotic drug, and shorter operative time in favor of patients undergoing PCNL. <sup>(6)</sup>

The most important consideration for achieving consistently successful outcomes in PCNL with minimal major complications is the correct selection of patients, a well-standardized technique, and good follow-up. <sup>(17)</sup>

Similarly, a proper access to the collecting system is the key requisite for any percutaneous renal procedure and the ideal tract would be that leads straight from the skin through a desired papilla and the target calyx into the renal pelvis in prone position because in this position, the kidneys are more fixed and least affected by the respiratory movements and the abdominal viscera were dropped down thus reducing their chances of injury during the procedure. <sup>(18)</sup>

Both ultrasonography and fluoroscopy have been recommended for

identification of the pelvicaliceal system, localization of the stone and puncture of the target calyx during percutaneous nephrolithotomy and the respective efficacies of both methods have been compared. <sup>(19)</sup> Montonari and associates recommended mixed ultrasonographic and fluoroscopic guidance for access to the collecting system. <sup>(20)</sup>

PCNL under fluoroscopic guidance generates significant radiation exposure to the surgeon and the radiation dose to the urologist averages milliroentgen (mR) per case. The radiation exposure during PCNL arises because of scattered radiation produced from the primary radiation beam, the patient, and the operating table. The areas of concern for exposure include the bone marrow, gonads, thyroid gland, and eye lens. <sup>(21)</sup>

The administration of contrast material to patients with renal failure may be harmful. <sup>(22)</sup> In addition, the contrast may overlie the opacity of the stone and may cause confusion when extravasations occur because of the inability to recognize the pelvicaliceal system. <sup>(23)</sup>

The use of ultrasonography as a guiding modality has a number of advantages such as lack of ionizing radiation, shorter operation time, fewer punctures, and no need for contrast agent administration. <sup>(24)</sup>

In pregnancy, fluoroscopy is contraindicated because of teratogenic effect and ultrasound guided access to the kidney is feasible. Other advantages of ultrasonography are detection of non-opaque stones, which are not visible with fluoroscopy, and also proper localization of the adjacent organs for prevention of injury.

The main disadvantage of this modality is difficulty with the approach



to a pelvicaliceal system with mild dilatation but this can easily be overcome by injecting 50-100 ml of saline through retrograde placement of ureteric catheter. (25)

In this study, we evaluate the efficacy and safety of PCNL under ultrasound guidance in Al Diwaniya Teaching Hospital for the treatment of renal stones, which has been the primary treatment modality in our hospital in the last three years.

Most of the patients in our study were young adults with an age range of 10-60 years with a mean age of  $35 \pm 4$  years. The most common age affected by stone is the fourth decade. The mean age of the patients was  $35 \pm 4$  years. The male to female ratio in our study was 1.63:1 which was comparable to other studies in which the male to female ratio was 2:1 which reflect that men are affected two times more frequently than women. (26)

Our operative time ranged from 45 to 110 minutes with a mean of  $71 \pm 7.4$  minutes which was comparable to Song Yan et al. and Firas Al-Hammouri who reported a mean operative time of  $66 \pm 2.5$  minutes and  $75 \pm 7.1$  minutes respectively. Xuede Qiu et al. reported that the operative time in the U/S group was significantly shorter than that in the fluoroscopy, and that the mean operative time was  $125.3 \pm 21.2$  minutes, and this may be explained by the need for more than one position and the C-arm technique that takes longer time than ultrasound. (27, 28, 29)

In our study, the stone-free rates in the immediate postoperative period and four weeks after PCNL without intervention were 84% and 90% respectively. With ancillary procedures

(ESWL & One URS), we achieved a stone-free rate of 100% at four weeks after the initial procedure, which was comparable to that achieved by other studies which were 89.07% and 92.0% respectively (30, 29). Our stone-free rate is better than that of Xuede Qiu et al. who used fluoroscopy as a guidance and obtained a stone-free rate which was (76.7%) (29) The better stone-free rate may be due to the fact that radiolucent stones may be missed in fluoroscopy.

In our study, intraoperative stone clearance was confirmed by rigid nephroscopy and ultrasonography. Although rigid nephroscopy is not a reliable tool for intraoperative stone searching, we depended on it due to unavailability of flexible nephroscopy in our center. Searching for residual stones with the use of ultrasound by experienced urologists is invaluable especially when dealing with radiolucent stones. (24)

Intraoperative and postoperative bleeding are considered the most common complications of percutaneous nephrolithotomy. Acute bleeding requiring blood transfusion after PCNL ranged from 1-10% depending on the experience of the operating surgeon. In our study, only one patient (1%) developed intraoperative bleeding that was treated with blood transfusion. Our intraoperative bleeding was comparable to that achieved by other studies, which was 1.6% (31). Xuede Qiu A et al. report a 1.5% intraoperative bleeding in PCNL under fluoroscopy, and 3.1% intraoperative bleeding in PCNL under ultrasound guidance. (29)

Most of the complications after ultrasound guided PCNL are not severe and usually settle down with

conservative treatment. Usman and colleagues<sup>(32)</sup> report their experience with ultrasound guided PCNL in 300 patients, where the overall complication rate was 50.8%, and fever was the most common complication (27.6%). In our study, nine patients (9%) developed mild fever which settled down with antipyretics and routine antibiotics. Hosseini and colleagues<sup>(33)</sup> reported postoperative ureteric colic in 17% cases after ultrasound guided PCNL, while in our study the incidence of postoperative ureteric colic was 7%, which were treated with nonsteroidal anti-inflammatory drugs. No injury to the adjacent organs occurred in our patients as the ultrasound can easily identify the adjacent organs and avoid them.

### CONCLUSION

PCNL under ultrasonographic guidance (both in caliceal puncture and tract dilation) is an effective and safe method for treatment of renal stone as it is not associated with radiation hazards to the operative staff, and it decreases intraoperative time and intraoperative bleeding and visceral injury and achieves comparable stone clearance rate.

### RECOMMENDATIONS

We recommend:

1. PCNL under ultrasonographic guidance is better to replace PCNL under fluoroscopic guidance.
2. All urologists should be trained very well on the ultrasound of the urinary system before trying to perform PCNL under ultrasonographic guidance.
3. Searching for residual stones should be done with the use of

flexible nephroscopy in addition to ultrasound.

4. Further studies to assess the safety and efficacy of PCNL under U/S guidance is needed.

### REFERENCES

1. Stefanos Papadoukakis, Jens-Uwe Stolzenburg, Michael C. Truss: Treatment Strategies of Ureteral Stones. Eau - ebu update series 4, 184–190, 2006.
2. Hubner WA, Porpaczy P (1990) Treatment of calyceal calculi. Br J Urol, 2013 66:9–11.
3. Albala DM, Assimos DG, Clayman RV, et al. Lower pole I: a prospective randomized trial of extracorporeal shock wave lithotripsy and percutaneous nephrostolithotomy for lower pole nephrolithiasis-initial results. J Urol 2001; 166(6):2072–80.
4. Fernström I, B Johansson B. Percutaneous pyelolithotomy. A new extraction technique. Scand J Urol Nephrol 1976; 10: 257-9.
5. Osman M, Wendt-Nordahl G, Heger K, Michel MS, Alen P, Knoll T. Percutaneous nephrolithotomy with ultrasonography-guided renal access: Experience from over 300 cases. BJU Int 2005; 96: 875-8.
6. Snyder JA, Smith AD, Staghorn calculi: percutaneous extraction versus anatomic nephrolithotomy. J Urol 1986; 136: 351-4.
7. Miller RA, Wickham JE. Percutaneous nephrolithotomy: Advances in equipment and endoscopic techniques. Urology 1984; 23: 2-6.
8. Rizvi SA, Naqvi SA, Hussain Z, Hashmi A, Hussain M, Zafar MN, et al. The management of stone disease. BJU Int. 2012; 89(suppl 1):62–68. PMID: 11876736.
9. Mahesh Desai. Ultrasonography-guided punctures with and without Puncture Guide. J Endourol 2009; 23: 1641-3.
10. Karami H, Arbab A. Novel technique for percutaneous nephrolithotomy in lateral decubitus flank position. J Urology 2007; 70: 177-9.
11. Basiri A, Ziaee SAM, Nasseh H, Kamranmanesh M, Masoudy P, Heidary F, et al. Totally Ultrasonography-guided Percutaneous Nephrolithotomy in the flank. J Endourol 2008; 22: 1453-8.
12. Zhou X, Gao X, Wen J, Xiao C. Clinical value of minimally invasive percutaneous nephrolithotomy in the supine position under the

- guidance of real-time ultrasound: report of 92 cases. *Urol Res* 2008; 36: 111-4.
13. Basiri A, Sichani MM, Hosseini SR, Vadjargah AM, Shakhssalim N, Kashi AH, et al. X-ray-free percutaneous nephrolithotomy in supine position with ultrasound guidance. *W J Urol* 2010; 28: 239-44.
14. Marino G, Gamba P, Del Noce G, Pugno A, Bradac R, Garberoglio R, et al. Intraoperative localization and management of renal calculi during nephrolithotomy by real-time ultrasonography. *Arch Ital Urol Androl* 2002; 74: 197-9.
15. Srirangam SJ, Darling R, and Stopford M, Neilson D. Contemporary practice of Percutaneous Nephrolithotomy: review of practice in a single region of UK. *Ann R Coll Surg Engl* 2008; 90: 40-4.
16. Falahatkar S, Panahandeh Z, Saurati A, Enshaei A, Esmaili S, Afsharimoghadam A. Percutaneous nephrolithotomy vs open surgery for patients with renal staghorn stones. *UroToday Int J* 2009; 2: doi:10.3834/uij.1944-5784.2009.10.09.
17. Michel MS, Trojan L, Rassweiler JJ. Complications in percutaneous nephrolithotomy. *Eur Urol* 2007; 51: 899-906.
18. Mahesh Desai. Ultrasonography-guided punctures with and without Puncture Guide. *J Endourol* 2009; 23: 1641-3.
19. Basiri A, Ziaee AM, Kianian HR, Mehrabi S, Karami H, Moghaddam SMH. Ultrasonographic versus fluoroscopic access for percutaneous nephrolithotomy: A randomized clinical trial. *J Endourol* 2008; 22: 281-4.
20. Montanari E, Serrago M, Esposito N, Rocco B, Kartalas-Goumas I, Dell Nero A, et al. Ultrasound fluoroscopy guided access to the intrarenal excretory system. *Ann Urol (Paris)* 1999; 33: 168-81.
21. Bush WH, Brannen GE, Gibbons AP, Correa RJ Jr, Elder JS. Radiation exposure to patient and urologist during percutaneous nephrostolithotomy. *J Urol* 1984; 132: 1148-52.
22. Karami H, Rezaei A, Mohammad hosseini M, Javanmard B, Mazloomfard M, Lotfi B. Ultrasonography-Guided percutaneous nephrolithotomy in the flank position versus Fluoroscopy-Guided percutaneous nephrolithotomy in the prone position: A comparative study. *J Endourol* 2010; 24: 1357-61.
23. Gamal WM, Hussein M, Aldahshoury M, Hammady A, Osman M, Moursy E, et al. Solo Ultrasonography-Guided percutaneous nephrolithotomy for single stone pelvis. *J Endourol* 2011; 25: 593-6.
24. Zegel HG, Pollack HM, Banner MC, Goldberg BB, Arger PH, Mulhern C, et al. Percutaneous nephrostomy: comparison of sonographic and fluoroscopic guidance. *AJR Am J Roentgenol*, 2005; 137: 925-927.
- 25-Manohar T, Jain P, Desai M. Supine percutaneous nephrolithotomy: effective approach to high-risk and morbidly obese patients. *J Endourol* 2007; 21: 44-9.
26. Kara C et al. A randomized comparison of totally tubeless and standard percutaneous nephrolithotomy in elderly patients. *Urology*. 2010; 76(2):289-93.
27. Song Yan, Fei Xiang and Song Yongsheng. Percutaneous nephrolithotomy guided solely by ultrasonography: a 5-year study of >700 cases. *Urology*. 2012; 43(2):221-34.
28. Firas Al-Hammouri, Adnan Abu-Qamar, Awad Kaabneh, Baker Abadi, Hazem Haboub. Percutaneous nephrolithotomy for management of large renal stones, Experience at Prince Hussein Bin Abdullah Urology Center 2009; 93(6):122-8.
29. Xuede Qiu\*, Zehui Li, Kewei Fang, Guihua Cao, Zhipeng Li, Jin He, Shunhui Yuan, Shucheng He, Zhi Wang and Jinrong Li Ultrasonography-Guided Versus Fluoroscopy-Guided Modified Minimally Percutaneous Nephrolithotomy for Staghorn Calculi: A Comparative Study 2015; 19: 208-213.
30. Mohammad Mehdi Hosseini, Alireza Yousefi and Mohsen Rastegari1, Pure ultrasonography-guided radiation-free percutaneous nephrolithotomy: report of 357 cases, 2015; 4:313
31. Anayat Ullah, Muhammad Kamran Khan, Ata Ur Rahman, Muhammad Naeem, Sarhad Khan, Riaz Ur Rehman. Otal ultrasound guided percutaneous nephrolithotomy: A novel technique 2012; 29: 218-223.
32. Osman M, Wendt-Nordahl G, Heger K, Michel MS, Alen P, Knoll T. Percutaneous nephrolithotomy with ultrasonography-guided renal access: Experience from over 300 cases. *BJU Int* 2005; 96: 875-8.
33. Hosseini MM, Hassanpour A, Farzan R, Yousefi A, Afrasiabi MA. Ultrasonography-

Guided percutaneous nephrolithotomy. J Endourol 2009; 23: 603-7.